

# EVALUATION OF MAXILLARY SINUS AND NASAL FLOOR AFTER IMPLANTOLOGICAL SURGERIES

**Mayer G.<sup>1</sup>, Klampfl A., Adili S.**  
 Department of Oral Surgery and Radiology<sup>1</sup>  
 Medical University Graz



## Introduction

The availability of sufficient vertical and horizontal bone is the precondition for any insertion of dental implants. The vertical bone volume in the upper jaw is limited by such structures as the maxillary sinus and the nasal floor. Consequently, there is a potential for perforations of implants in these regions. The aim of this latest follow-up examination is to assess the prevalence of dental implants in the maxillary sinus and the nasal floor as well as the resulting long-term clinical and radiologic complications. Furthermore, the significance of orthopantomograms as compared with 3D diagnostic radiology (CT or DVT) regarding the position of the implant in proportion to the nasal floor, respectively to the maxillary sinus after implantations with or without maxillary sinus floor augmentation will be examined.

## Materials and Method

Over a six-year period from 2002 to 2008, a total number of 683 upper jaw implants were inserted to altogether 313 patients at the Department of Oral Surgery and Radiology at the Medical University Graz. A number of 36 patients, corresponding 124 implants, agreed to a follow-up examination. The latter consisted of a standardized clinical and radiological (orthopantomogram and CT/DVT) examination.

## Results

33.4% (n=228) of the total of 683 implants inserted in the upper jaw revealed a perforation of the maxillary sinus floor, respectively of the nasal floor (cf. Table 1) on the postoperative orthopantomogram.

The current orthopantomograms of the follow-up examination (6 – 82 months post-surgery,  $\bar{x}$  50.11 months) illustrate that 41.13% (n=51) of the implant apices of the total of 124 checked-up implants were located above (0.8mm - 9.2mm,  $\bar{x}$  3.22mm) the nasal/maxillary sinus floor (cf. Figure 1 and Figure 2). 16.94% (n=21) are exactly on the level of the nasal/maxillary sinus floor and 41.93% (n=52) beneath (cf. Table 2). The total survival rate of the checked-up implants was 96.77% ( $\bar{x}$  50.1 months).

In cases with radiologic detected perforations, clinical symptoms were observed in 2.78% (n=1) and radiologic pathology in 5.55% (n=2) (cf. Table 3). The consistency ratio (orthopantomogram vs. CT/DVT) with regard to the position of the implants was 69.56%.

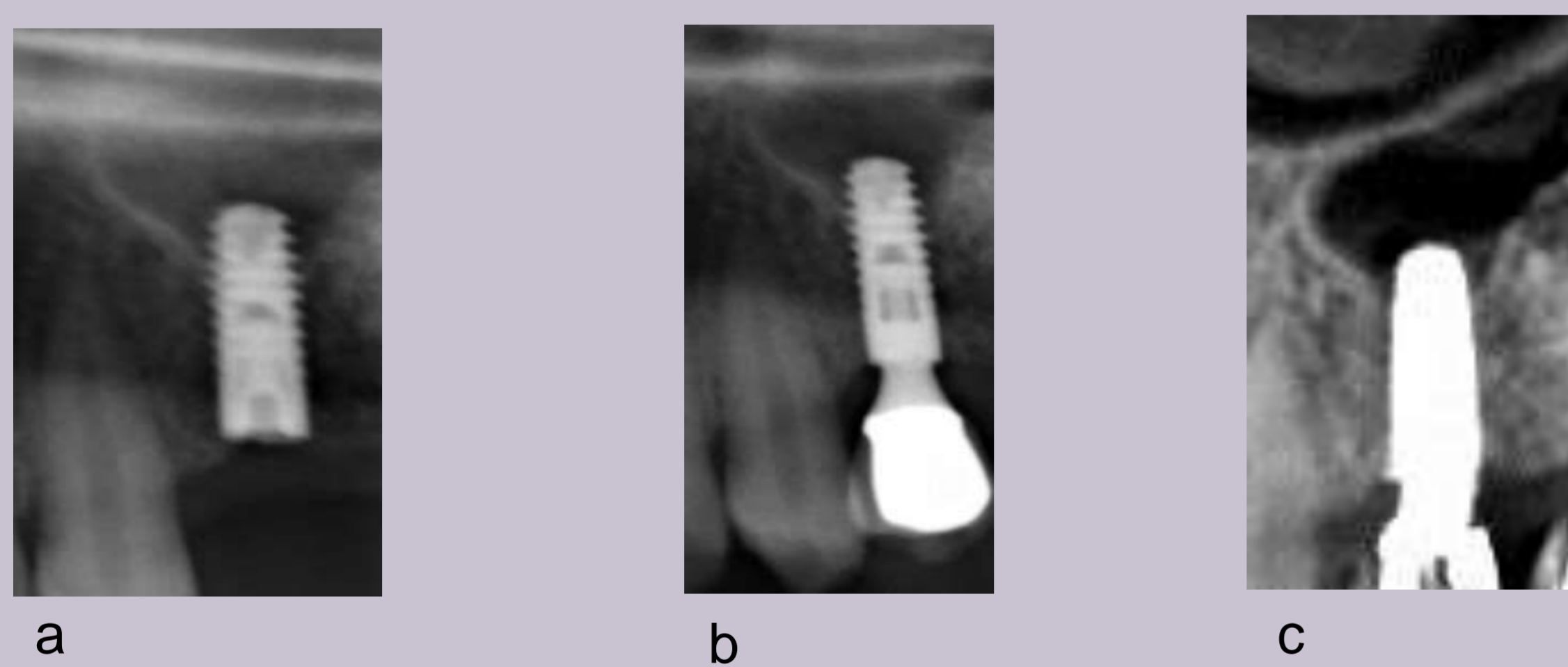


Figure 1: Radiologic perforation to maxillary sinus  
 a: Postoperative result, OPG detail  
 b: 2 years postoperative, OPG,  
 c: 2 years postoperative, DVT

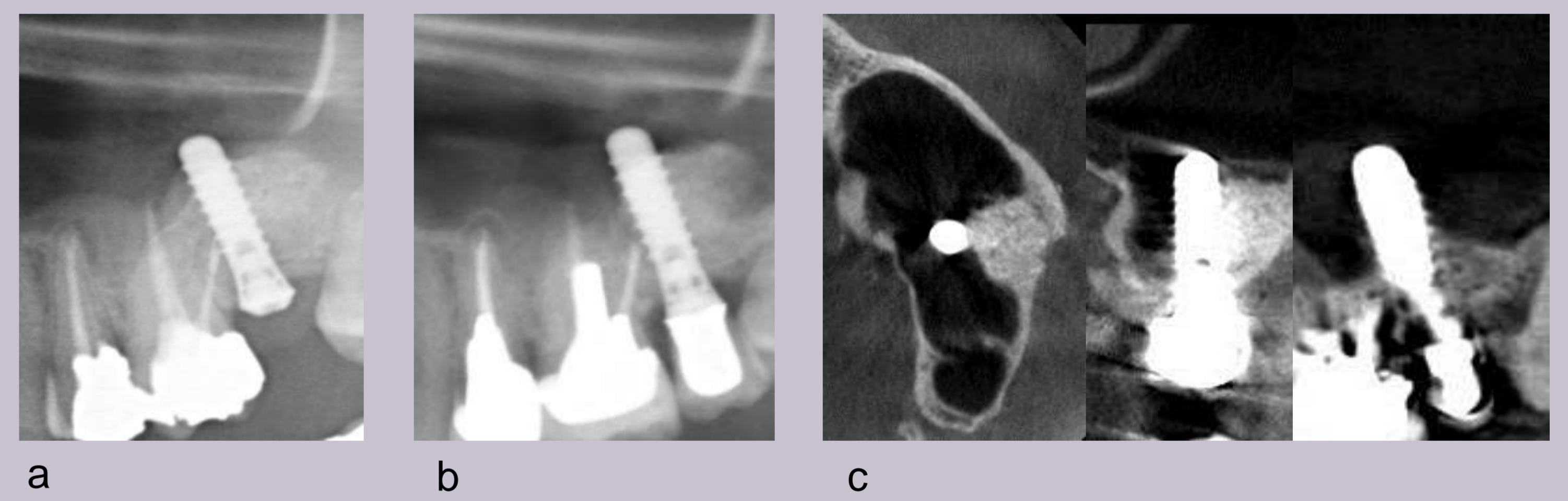


Figure 2: Radiologic perforation after maxillary sinus floor augmentation and implantation  
 a: Postoperative result, OPG  
 b: 5 years postoperative, OPG  
 c: 5 years postoperative, DVT (axial, coronal, sagittal) result

| Total number of implants inserted between 2002 and 2008                | n=683 | 100 % |
|--|-------|-------|
| Perforated   | 228   | 33.4% |
| Bordering on the maxillary sinus floor or nasal floor (non-perforated) | 45    | 6.6%  |
| Beneath the maxillary sinus or nasal floor (non-perforated)            | 410   | 60%   |

Table 1: Evaluation of all implants (n=683) based on postoperative orthopantomogram

| Checked-up implants  | n=124 | 100 % |
|--|-------|-------|
| Perforated   | 55    | 44.3% |
| Bordering on the maxillary sinus floor or nasal floor (non-perforated) | 18    | 14.6% |
| Beneath the maxillary sinus or nasal floor (non-perforated)            | 51    | 41.1% |

Table 2: Evaluation of all follow-up implants (n=124) based on current orthopantomograms

| Perforations after CT/ DVT analysis | n=36 |      |
|-------------------------------------|------|------|
| Clinical condition                  | 1    | 2.8% |
| Radiologic pathologies (sinusitis)  | 2    | 5.6% |

Table 3: CT/DVT Analysis of radiologically verified perforations

## Conclusion

The results of the latest follow-up examinations exhibit a relatively frequently occurring close position, respectively perforation of implants in the nasal floor or the maxillary sinus on the orthopantomogram, whereas the 3D diagnostic (CT/DVT) proves to be much more sensitive. Clinical symptoms (2.78%) and radiologic pathologies (5.55%) are rare.